European Journal of Orthopaedic Surgery & Traumatology
https://doi.org/10.1007/s00590-018-2183-1

TECHNICAL NOTE • SHOULDER - ARTHROSCOPY

Superior capsular reconstruction of the shoulder: the ABC (Arthroscopic Biceps Chillemi) technique

Claudio Chillemi[1] · **Matteo Mantovani**[2] · **Antonio Gigante**[3]

Received: 19 January 2018 / Accepted: 12 March 2018
© Springer-Verlag France SAS, part of Springer Nature 2018

Abstract

Superior capsular reconstruction (SCR) demonstrated its efficacy as a treatment option available in patients affected with irreparable posterosuperior rotator cuff tears without any signs of arthritis. Originally, the fascia lata autograft was fixed medially to the glenoid (with two or more anchors) and laterally to the greater tuberosity (with a compression double-row technique using four anchors or three transosseous tunnels). Additionally, side-to-side sutures were used to anteriorly and posteriorly connect the graft to the native residual rotator cuff tissue. However, the fascia lata as an autograft has a disadvantage related to the donor-site morbidity. To solve this aspect, allografts were employed with initial promising results. Nowadays, SCR is to be considered a technically demanding and expensive procedure, because of the cost of the allograft plus that of all the anchors employed to fix it. The Arthroscopic Biceps Chillemi's technique addresses these concerns in performing SCR and presents numerous advantages being a safe, easier, time and cost-saving way compared to the other published techniques. This technique has only one *conditio sine qua non*: the presence of the long head of the biceps tendon (LHB), used as an autograft. This condition may be interpreted as a disadvantage of this procedure in the presence of some anatomic variations of the intra-articular portion of the LHB and the very rare absence of the tendon or in case of partial or complete rupture of the LHB tendon associated with a rotator cuff tear.

Keywords Rotator cuff · Irreparable · Tear · LHB tendon · Superior capsular reconstruction

Introduction

Rotator cuff tears are very common, and in most cases, a complete repair of even large or massive tears can be achieved [1]. However, a subset of patients exists in whom the rotator cuff tendon is either irreparable due to a fixed retraction or very poor tissue quality [2, 3]. These patients may complain a significant pain and weakness despite active overhead motion or in other cases may present shoulder pseudoparalysis [4]. In such cases, different options can be proposed. In addition to medical therapy associated with a rehabilitation program of deltoid strengthening, in the presence of concomitant arthritis and for patients who have pseudoparalysis, the reverse total shoulder arthroplasty (rTSA) seems the universally accepted option [4, 5]. The challenge is to choose the better treatment in those patients affected with an irreparable RC tear without shoulder arthritis. It appears quite clear how the surgical indications depend on the surgeon, and debridement with or without long head of biceps tenotomy, tuberoplasty, partial arthroscopic rotator cuff repair, interval slide, patch augmentation or muscular transfers may be different options for patients younger than 60 years who do not have pseudoparalysis [3, 6, 7]. Moreover, recently the superior capsular reconstruction (SCR) was proposed as a viable alternative [8]. In fact, patients with irreparable rotator cuff tears have a defect of the shoulder superior capsule which affects the motion of the humeral head, not only on the side of the lesion but in other directions as well, creating the yet known phenomenon called as "the circle concept" [9]. Capsular discontinuity is one of the causes underlying shoulder instability after rotator cuff tears [8, 10–12]. The SCR has been proposed with

✉ Claudio Chillemi
c_chillemi@libero.it

[1] Department of Orthopaedic Surgery, Istituto Chirurgico Ortopedico Traumatologico (ICOT), Via F. Faggiana, 1668 Latina, Italy

[2] NCS Lab, Srl, Carpi, Italy

[3] Clinical Orthopaedics, Università Politecnica delle Marche, Ancona, Italy

Published online: 21 March 2018

the aim to restore superior glenohumeral stability and function in the shoulder joint affected with irreparable rotator cuff tears [8, 13]. The original procedure provides the use of a fascia lata autograft that is attached medially to the superior glenoid and laterally to the greater tuberosity; additionally, the remnants of the rotator cuff tendons are side-to-side sutured with the graft (posteriorly the infraspinatus–teres minor tendon and anteriorly the subscapularis tendon) [8, 13]. The biomechanical role of the SCR was confirmed by different studies [8, 13, 14] demonstrating how the glenohumeral superior translation is significantly less when the graft is fixed medially to the glenoid than that after a tendon graft attached medially to the torn rotator cuff tendon [15]. During the last years, shoulder surgeons became interested in Mihata's original SCR technique [8], proposing some modifications, in particular regarding the choice of the graft, adapting dermal allograft [16].

SCR may be defined as a technically demanding procedure. Originally, the medial side of the graft was attached to the superior glenoid by using two anchors and, for lateral attachment of the graft, was used a transosseous technique that involved three bone tunnels created at the greater tuberosity [8]. Also this aspect was a topic of discussion, and different configurations with anchors were proposed to fix the graft laterally: To obtain a speed-bridge configuration, four anchors were advised [16].

In this paper, a novel and reproducible less-demanding all-arthroscopic SCR technique is reported with its early results. This technique has only one *conditio sine qua non*: the presence of the long head of the biceps tendon (LHB), used as an autograft [17].

Materials and methods

Between January and June 2017, nine patients (four males and five females, mean age 66.4 years ± 3) with a irreparable posterosuperior RCT underwent arthroscopic SCR performed by the first author (CC) using the technique below described. Inclusion criteria were: no previous shoulder surgery, injections and infection, irreparable posterosuperior RCT without glenohumeral arthritis and stiffness. Six cases (out of nine) presented a subscapularis tendon tear: two cases with a Type II and four cases with a Type III lesion according to Lafosse classification [18]. All patients were followed up after a minimum of 6 months clinically by the visual analog scale for pain (VAS; 0 = no pain, 10 = maximum pain). The paired *t* test was used to determine whether there was a significant difference between preoperative and postoperative VAS score obtained at the latest control at 6 months. A p value of < 0.05 was considered to be statistically significant.

Surgical technique

The procedure can be performed depending on anesthesiologist preference under general anesthesia or interscalene cervical plexus block or combined and in beach-chair position or lateral decubitus according to surgeon request. A three-portal surgical technique is suggested: standard posterior (for the scope), lateral and antero-superior (working) portals. Once the irreparability of the posterosuperior RC lesion is assessed, with an intact LHB tendon (Fig. 1) is possible to perform the ABC technique. In the presence of a subscapularis tendon tear, we recommend to repair it (in accordance with the surgeon preferred technique and after the LHB distal tenotomy is performed). First of all the bone bed of the greater tuberosity is prepared with a shaver and motorized burr to obtain a wide surface decortication of the footprint providing maximum spongy bone (Fig. 2). LHB tendon originates intra-articularly from the superior glenoid tubercle and courses through the intertubercular groove of the proximal humerus. LHB tenotomy is performed distally maintaining intact its glenoid origin, so that our biceps graft is yet medially fixed. According to the surgeon preference and/or patients request is possible to perform a biceps tenodesis into the groove with a knotless anchor. Otherwise, the distal part of the LHB tendon can be left free probably producing the undesirable cosmetic effect of the Popeye sign. Once repaired the subscapularis tendon if torn, at this point is possible to fix laterally to the greater tuberosity the LHB, choosing between a two-anchor or a two-transosseous tunnel fixation technique.

Two-anchor lateral fixation of the LHB

A suture tape (XBraid TT—1.2 mm, Braided Polyethylene, Stryker, USA) is passed twice through the anterior border of the tendon to obtain a good fixation without any risk of cut of the suture. The same procedure is then performed with another suture tape for the posterior border of the tendon (Fig. 3). A suture limb from each medial suture tapes is criss-crossed and loaded into the eyelet of a knotless anchor (ReelX STT 4.5 mm—Stryker) that will be used for lateral fixation. A total of two anchors are placed for lateral row fixation, one anteriorly and one posteriorly (Fig. 4). Ideal placement of these anchors is approximately 5–10 mm lateral to the edge of the greater tuberosity, where the bone quality improves [19]. The anterior anchor is placed first. This knotless anchor features an incremental tensioning mechanism. The PEEK body of the anchor expands with each incremental turn of the black knob on

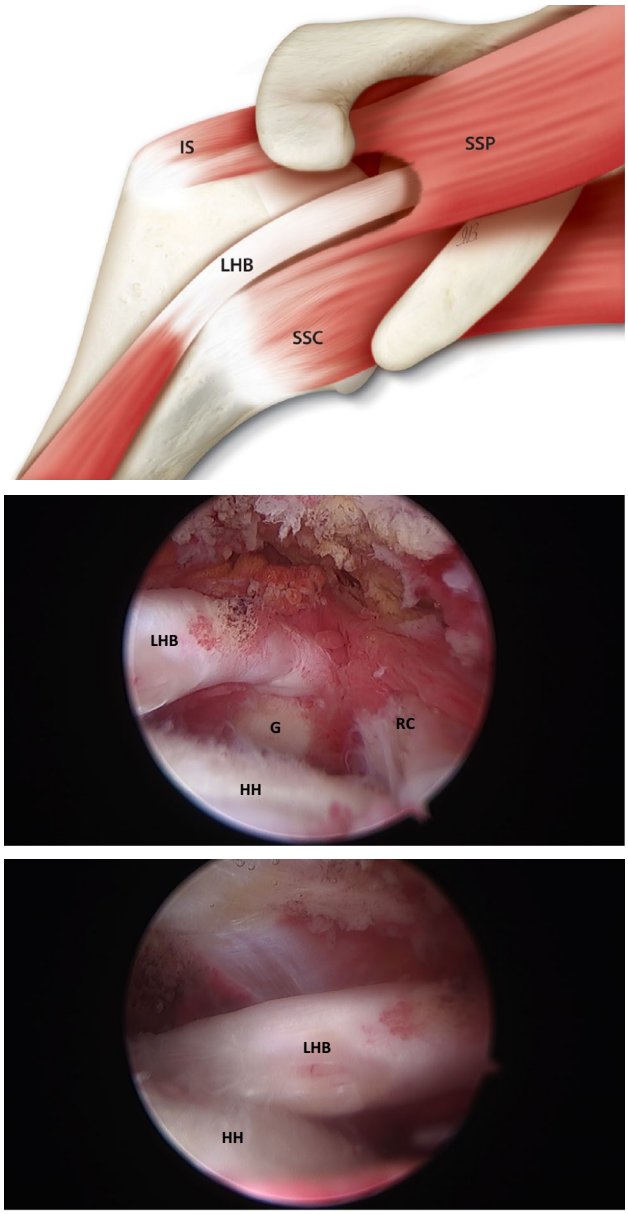

Fig. 1 Retracted rotator cuff tear (IS: infraspinatus; SSP: supraspinatus) appearance. Note the integrity of the long head biceps (LHB) and subscapularis (SSC) tendons. *Arthroscopic view*. Left shoulder. Lateral decubitus. Subacromial space. The scope is lateral (up) and posterior (down). The torn rotator cuff (RC) is retracted till the glenoid (G). The humeral head (HH) is exposed. The long head of biceps (LHB) is quite rounded. Note the synovitis

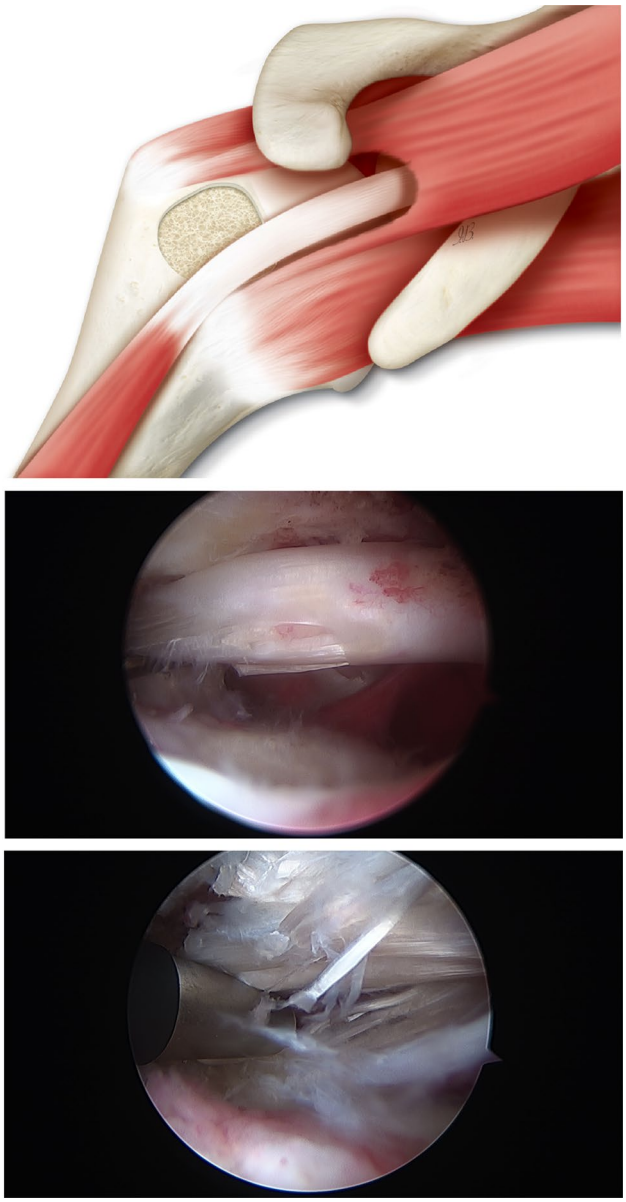

Fig. 2 Bone bed preparation of the greater tuberosity to obtain a wide surface decortication of the footprint providing maximum spongy bone. *Arthroscopic view*. Left shoulder. Lateral decubitus. Subacromial space. The scope is posterior. The LHB is firstly evaluated pulling a traction (up) before its distal tenotomy (down) with RF

the inserter handle, expanding up to one additional millimeter in diameter under the cortical surface, to provide enhanced fixation.

These steps are then repeated for the posterolateral anchor. The result is a quick, secure and low profile fixation with excellent contact between the graft (i.e., biceps tendon) and bone.

Two-transosseous tunnels lateral fixation of the LHB

It is possible to prepare the two TO tunnels required for this technique, in accordance with what has yet been described [20]. The device to perform the tunnels is named Taylor Stitcher® Evo (NCS Lab s.r.l.—Medical Devices Factory, Carpi—Italy) (Fig. 5). In this case, it is necessary to perform an additional lateral more inferior portal. It permits to perform the TO tunnel through the handle screwing that controls the advancement of a Superelastic Transosseous

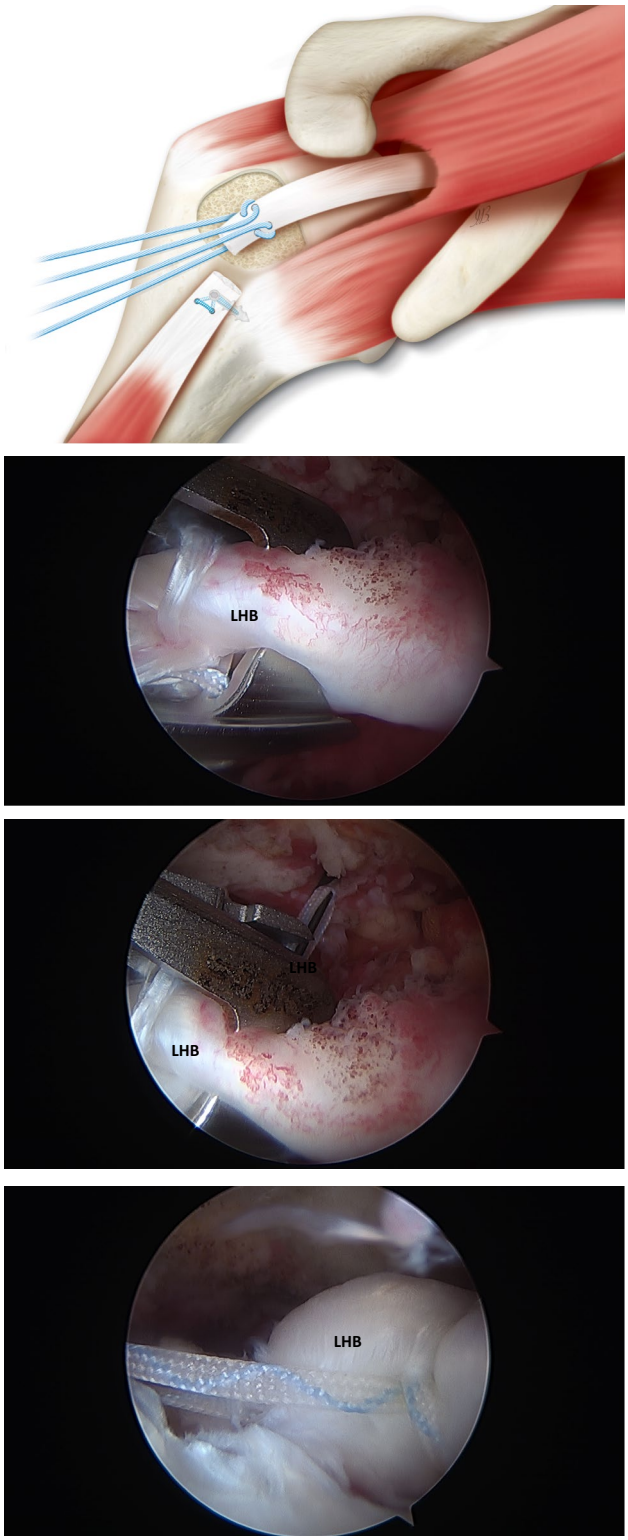

Fig. 3 SCR: *2-anchor lateral fixation of the LHB*. LHB tenotomy is performed distally maintaining intact its glenoid origin. Biceps tenodesis is performed into the groove with a knotless anchor. *Arthroscopic view*. Left shoulder. Lateral decubitus. Subacromial space. The scope is posterior. The LHB is prepared (up), passing twice a suture tape through the posterior border of the tendon with a suture passer able to retrieve the wire (middle), to obtain a loop (down) without any risk of cut of the suture. The same procedure is then performed with another suture tape for the anterior border of the tendon

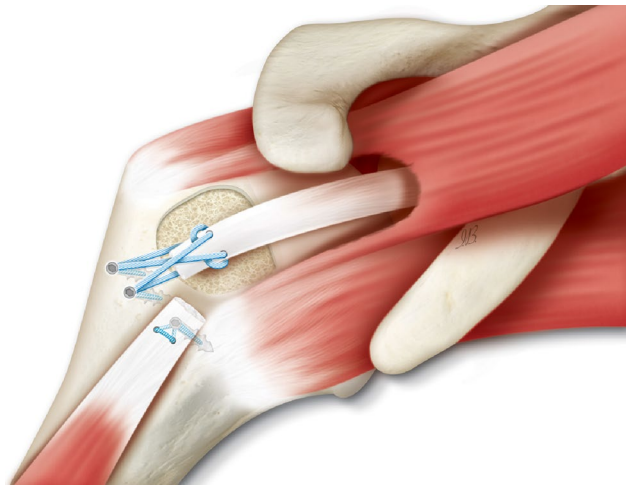

Fig. 4 SCR: *2-anchor lateral fixation of the LHB*. A suture limb from each of the medial suture tapes is criss-crossed and loaded into the eyelet of a knotless anchor that will be used for lateral fixation. A total of two anchors are placed for lateral row fixation, one anteriorly and one posteriorly

Fig. 5 The Taylor Stitcher Evo, a dedicated instrument to perform the transosseous tunnel

Needle® (STN) (NCS Lab s.r.l.—Medical Devices Factory, Carpi—Italy). Thanks to its multiradius shape, led by the position limiter, the Taylor Stitcher® Evo performs TO tunnels in the footprint area. Tunnels are 3 mm in diameter and present a smooth curved morphology. Once located the lateral cortical entry point (approximately at about 15–20 mm distally to the greater tuberosity), the anterior tunnel is prepared firstly. The same procedure is repeated to prepare another TO tunnel posteriorly, leaving a minimum bone bridge of approximately 10 mm between the two TO tunnels in AP direction. The shuttle wire is then passed in one single step with the STN (having an eyelet close to the tip) through the TO tunnel so that the suture wires can be dragged into it. To make easier and safe this step is better to have a loop instead of a single extremity of the shuttle wire. It is possible to obtain it only with a CC trick (i.e., Claudio Chillemi trick) in mounting the shuttle wire into the STN (Fig. 6), so to have yet ready the shuttle wire in a loop configuration (Fig. 7). With the preferred instrumentation, the surgeon passes the

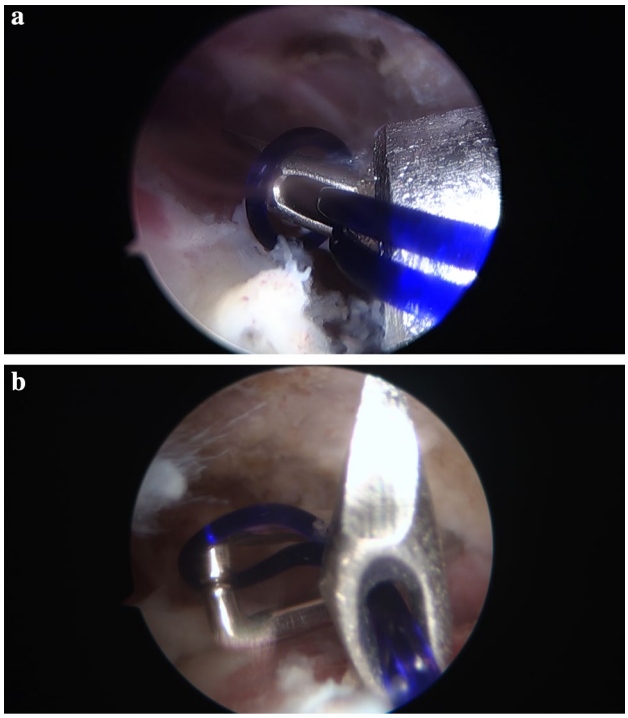

Fig. 6 SCR: *2-TO tunnel lateral fixation of the LHB. Arthroscopic view*. Right shoulder. Subacromial space. The scope is posterior. The shuttle wire is mounted into the STN in accordance with the CC trick (up) to obtain directly a loop—once the transosseous tunnel is performed and the needle comes out through the greater tuberosity (down)

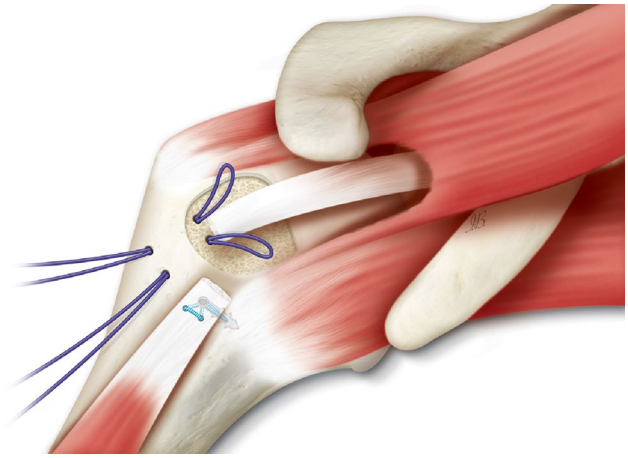

Fig. 7 SCR: *2-TO tunnel lateral fixation of the LHB.* Two TO tunnels are prepared starting from the lateral cortex of the humerus leaving a minimum bone bridge of approximately 10 mm between the tunnels in AP direction. The shuttle wire is then passed in one single step with the STN in a loop configuration (according to the CC trick)

loop through the biceps tendon anteriorly and posteriorly (in line with the exit hole of the TO tunnels) (Fig. 8). Each shuttle wire is then used to pass one extremity of a smooth

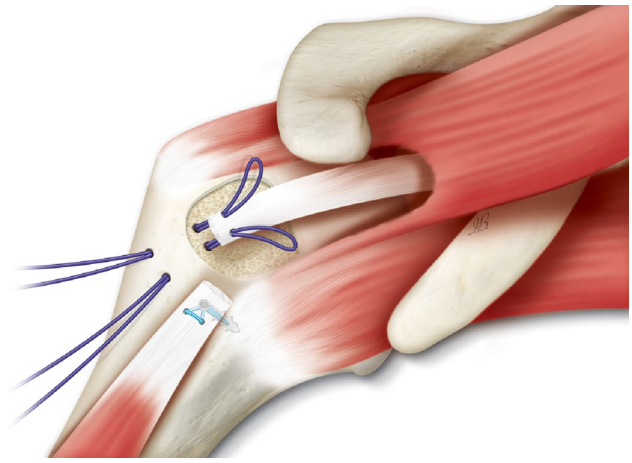

Fig. 8 SCR: *2-TO tunnel lateral fixation of the LHB.* Both the loops are passed through the biceps tendon anteriorly and posteriorly (in line with the exit hole of the TO tunnels)

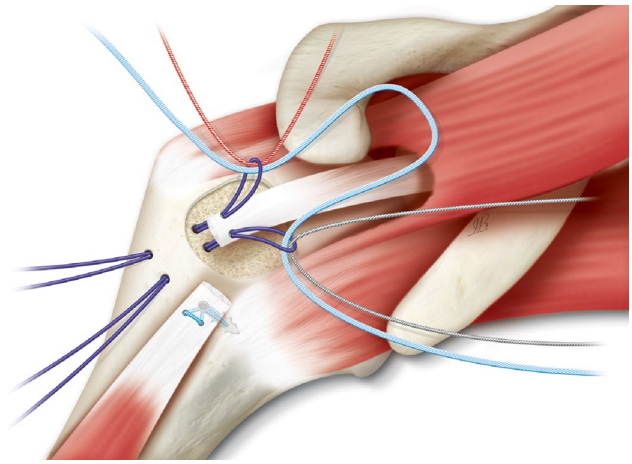

Fig. 9 SCR: *2-TO tunnel lateral fixation of the LHB.* Each shuttle wire is then used to pass through the tendon and the bony tunnels three sutures (one tape and two high resistance sutures). The tape is passed in both loops, while the high resistance sutures are, respectively, passed one in the anterior and one in the posterior loop

suture tape (XBraid TT—1.2 mm, Braided Polyethylene, Stryker, USA) and one extremity of a high resistance suture (Zipline#2, Stryker, USA) through the biceps tendon and through the TO tunnel so that one extremity of the tape is passed through the anterior aspect of the medial portion of the tendon and the anterior TO tunnel and the other one is passed through the posterior aspect of the medial portion of the biceps tendon and the posterior TO tunnel (like a reverse "U") (Fig. 9). Both extremities of the tape and of the sutures are then retrieved from the lateral cortical entry points of the tunnels through the lateral portal.

The simple sutures are passed twice, respectively, through the anterior and posterior border of the tendon (so to avoid

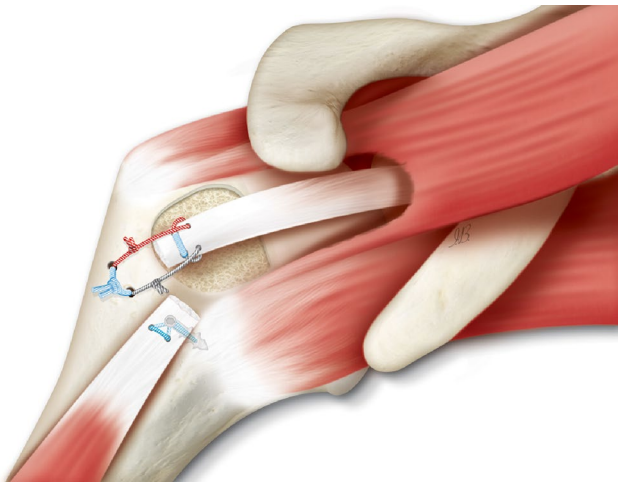

Fig. 10 SCR: *2-TO tunnel lateral fixation of the LHB*. Both extremities of the tape and of the sutures are then retrieved from the lateral cortical entry points of the tunnels through the lateral portal. The simple sutures are passed twice, respectively, through the anterior and posterior border of the tendon (so to avoid any cut through the tendon) before tying the knot. The medial mattress suture is then completed performing an arthroscopic knot on the lateral cortex of the greater tuberosity

any cut through the tendon). Before knot tying, the pressure effect of the mattress suture onto the footprint can be proved by pulling the suture ends. The medial mattress suture is then completed performing an arthroscopic knot on the lateral cortex of the greater tuberosity. After tying the knot, the two extremities of the tape are cut. Later close with two simple knots the additional anterior and posterior sutures so to tightly secure the biceps (Fig. 10).

Once the LHB is fixed, it is possible to perform a partial side-to-side repair (Fig. 11) of the residual cuff over the top of the biceps passing a suture through the infraspinatus tendon and into the posterior margin of the biceps. Anterior margin convergence can aid in biceps tensioning even if sometimes the rotator interval tissues can be absent. Care should be taken not to over-constrain the shoulder anteriorly by attaching the graft to the subscapularis. This would be equivalent to closing the rotator interval. The anterior and posterior margin convergence is necessary to center the humeral head preventing subluxation. Acromioplasty is not performed, and the coracoacromial ligament is preserved so to prevent superior migration of the humeral head.

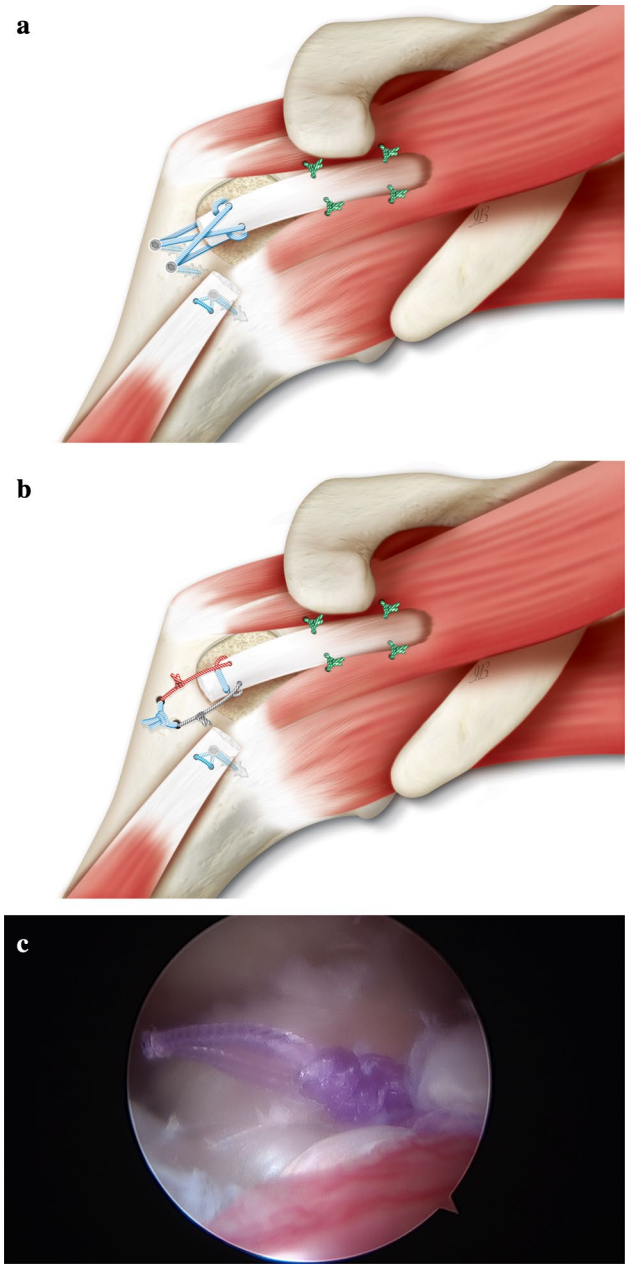

Fig. 11 (**a**–**c**). SCR: ABC technique. Final construct. Once the LHB is fixed, it is possible to perform a partial side-to-side repair between the biceps and the residual cuff tissue. **a** *Two-anchor lateral fixation of the LHB*. **b** *Two-transosseous tunnel lateral fixation of the LHB*. **c** *Arthroscopic view*. Left shoulder. Lateral decubitus. Subacromial space. The scope is posterior. The humeral head is no more exposed and covered by the tendinous tissue of the LHB partially sutured with the remnant of the cuff (the violet knot in orthocord is fixing the posterior border of the LHB with the residual posterior cuff)

Postoperative rehabilitation protocol

Postoperatively, the arm was placed in an abduction pillow at 20°, which was maintained for 30 days. Passive shoulder mobilization and active hand, wrist and elbow exercises started from the first day after surgery. Active-assisted shoulder exercises were allowed from the first month post-op, and from the second month strengthening exercises of the deltoid were allowed.

Preliminary results

No intraoperative or postoperative complications were encountered. The LHB was laterally fixed in five cases with two anchors and in four cases with two transosseous tunnels. In no case biceps tenodesis was performed: Popeye sign was easily detected in four patients. In the remnant five cases, it was covered by the well-represented subcutaneous tissue of the superior arm of the patients. All the six subscapularis tendon tears were arthroscopically repaired in all cases with one additional anchor. The mean VAS score significantly improved from 7.2 to 2.3 ($p < 0.01$). No difference was found between patients with (6/9) and without (3/9) subscapularis tendon tear repaired and if the LHB was laterally fixed with two anchors (5/9) or with two transosseous tunnels (4/9). Operative time did not significantly differ between two-anchor and two-TO tunnel lateral fixation of LHB. Average case time (excluding the time necessary to repair the subscapularis tendon) in the two-anchor group varied from 46 to 58 min and from 52 to 65 min in the two-TO tunnel group.

Discussion

During the last few years, literature mostly dealt with the treatment options available in patients affected with irreparable posterosuperior rotator cuff tears without any signs of arthritis, and superior capsular reconstruction demonstrated its efficacy [1, 21–28]. In accordance with the original technique and later modifications [8], the fascia lata autograft was fixed medially to the glenoid (with two or more anchors) and laterally to the greater tuberosity (with a compression double-row technique using four anchors or three transosseous tunnels). Additionally, side-to-side sutures were used to anteriorly and posteriorly connect the graft to the native residual rotator cuff tissue to restore anterior and posterior force couples.

However, some major concerns come out from the data available in the literature, and in particular about the choosing the graft and its fixation. The fascia lata as an autograft has a disadvantage related to the donor-site morbidity. To solve this aspect, allografts were employed with initial promising results. But, recently the biomechanical and clinical results of the SCR using fascia lata as the graft have been compared with single-layered human dermal allograft. The latter—due to its greater flexibility, was able to partially restore superior glenohumeral stability, whereas fascia lata allograft completely restored the superior glenohumeral stability [25].

The described techniques in addition to being technically demanding are surely expensive, because of the cost of the allograft plus that of all the anchors employed to fix it. The Arthroscopic Biceps Chillemi's technique addresses these concerns in performing SCR and presents numerous advantages:

1. the LHB tendon is an autograft without any donor-site morbidity
2. the LHB as an autograft is cost-saving
3. the LHB as the fascia lata is a tendon and for this reason biomechanically superior to dermal allograft
4. the LHB tendon maintains its origin and its vascular pedicle, so it is vital
5. the LHB tendon is yet fixed medially to the upper part of the glenoid, and this aspect implies no needs to fix it. In other words, it means: no needs to use anchors, makes surgery easier or less demanding, reduces the operative time and consequently reduces the costs
6. the LHB lateral fixation does not present particular skills, being the shoulder surgeon more confident to fix a tendon into the greater tuberosity. Moreover, in comparison with the yet published technique this step is easier—quicker and cheaper employing only two knotless anchors or two TO tunnels

The only disadvantage of this procedure is represented by some anatomic variations of the intra-articular portion of the LHB and the very rare absence of the tendon [29] or as a consequence of rotator cuff tear in which LHB may be involved in partial (16%) or complete rupture (7%) [30].

In case of this evenience may be advised the employment of biologic products guided by sound evidence and cost–benefit considerations [4].

The current paper presents some conceptual similarities with the recently published "Chinese way" to reconstruct the superior capsule of the shoulder [17], with differences in the arthroscopic technique (number of portals required and lateral fixation of the tendon). In addition in this study a major concern was addressed. It is known that the LHB is considered as a shoulder pain generator [31], and its employment in the SCR could be responsible for a really discomfortable painful shoulder. For this reason, before publishing this technique we carefully clinically evaluated for the first six months all the operated patients to address this doubt. The early promising results of the ABC technique showed that the use of the SCR is safe and is not associated with an increase in postoperative pain for the first 6 months.

Conclusion

The current technique allows to perform an all-arthroscopic SCR in a safe, easier, time- and cost-saving way compared to the other published techniques. However, even if this

technique is less demanding, the arthroscopic SCR is still an advanced procedure and should be performed only by well-prepared arthroscopic shoulder surgeons. Further clinical trials are needed to investigate the long-term benefit of this technique.

Acknowledgements A special thanks to Miss Ilaria Bondi, medical graphic designer (www.illustrazionianatomiche.com), for preparing all the illustrations of this paper.

Compliance with ethical standards

Conflict of interest Claudio Chillemi declares that he has no conflict of interest. Matteo Mantovani designed and manufactured the Taylor Stitcher Evo® + Superelastic Transosseous Needle®. Antonio Gigante declares that he has no conflict of interest.

Ethical approval All procedures performed in studies involving human participants were in accordance with the ethical standards of the institutional and/or national research committee and with the 1964 Helsinki Declaration and its later amendments or comparable ethical standards.

Informed consent Informed consent was obtained from all individual participants included in the study.

References

1. Adams CR, Denard PJ, Brady PC, Hartzler RU, Burkhart SS (2016) The arthroscopic superior capsular reconstruction. Am J Orthop 45(5):320–324
2. Chillemi C, Petrozza V, Garro L, Sardella B, Diotallevi R, Ferrara A, Gigante A, Di Cristofano C, Castagna A, Della Rocca C (2011) Rotator cuff re-tear or non-healing: histopathological aspects and predictive factors. Knee Surg Sports Traumatol Arthrosc 19(9):1588–1596
3. Narvani AA, Imam MA, Polyzois I, Sarkhel T, Gupta R, Levy O, Consigliere P (2017) The "Pull-Over" technique for all arthroscopic rotator cuff repair with extracellular matrix augmentation. Arthrosc Tech 6(3):e679–e687
4. Burkhart SS, Denard PJ, Adams CR, Brady PC, Hartzler RU (2016) Arthroscopic superior capsular reconstruction for massive irreparable rotator cuff repair. Arthrosc Tech 5(6):1407–1418
5. de Cupis V, Chillemi C, Marinelli M (2008) Grammont inverted prosthesis for the treatment of cuff tear arthropathy: a 6-year follow-up study. Orthopedics 31(5):447–452
6. Burkhart SS, Nottage WM, Ogilvie-Harris DJ, Kohn HS, Pachelli A (1994) Partial repair of irreparable rotator cuff tears. Arthroscopy 10:363–370
7. Merolla G, Chillemi C, Franceschini V, Cerciello S, Ippolito G, Paladini P, Porcellini G (2015) Tendon transfer for irreparable rotator cuff tears: indications and surgical rationale. Muscles Ligaments Tendons J 4(4):425–432
8. Mihata T, Watanabe C, Fukunishi K, Tsujimura T, Ohue M, Kinoshita M (2010) Clinical outcomes after arthroscopic superior capsular reconstruction for irreparable rotator cuff tear. Shoulder Joint 34:451–453
9. Schwartz E, Warren RF, O'Brien SJ, Fronek J (1987) Posterior shoulder instability. Orthop Clin North Am 18:409–419
10. Neer CS 2nd, Craig EV, Fukuda H (1983) Cuff-tear arthropathy. J Bone Joint Surg Am 65:1232–1244
11. Boileau P, McClelland WB Jr, Rumian AP (2014) Massive irreparable rotator cuff tears: how to rebalance the cuff-deficient shoulder. Instr Course Lect 63:71–83
12. Paxton ES, Dodson CC, Lazarus MD (2014) Shoulder instability in older patients. Orthop Clin North Am 45:377–385
13. Mihata T, McGarry MH, Pirolo JM, Kinoshita M, Lee TQ (2012) Superior capsule reconstruction to restore superior stability in irreparable rotator cuff tears: a biomechanical cadaveric study. Am J Sports Med 40:2248–2255
14. Mihata T, McGarry MH, Kahn T, Goldberg I, Neo M, Lee TQ (2016) Biomechanical role of capsular continuity in superior capsule reconstruction for irreparable tears of the supraspinatus tendon. Am J Sports Med 44(6):1423–1430
15. Limpisvasti O, Yang BY, Hosseinzadeh P, Leba TB, Tibone JE, Lee TQ (2008) The effect of glenohumeral position on the shoulder after traumatic anterior dislocation. Am J Sports Med 36:775–780
16. Burkhart SS, Ricchetti ET, Levine WN, Galatz LM (2016) Challenges and controversies in treating massive rotator cuff tears. Instr Course Lect 65:93–108
17. Boutsiadis A, Chen S, Jiang C, Lenoir H, Delsol P, Barth J (2017) Long head of the biceps as a suitable available local tissue autograft for superior capsular reconstruction: "The Chinese Way". Arthrosc Tech 6(5):e1559–e1566
18. Lafosse L, Jost B, Reiland Y, Audebert S, Toussaint B, Gobezie R (2007) Structural integrity and clinical outcomes after arthroscopic repair of isolated subscapularis tears. J Bone Joint Surg Am 89(6):1184–1193
19. Zumstein MA, Raniga S, Labrinidis A, Eng K, Bain GI, Moor BK (2016) Optimal lateral row anchor positioning in posterior-superior transosseous equivalent rotator cuff repair: a micro-computed tomography study. Orthop J Sports Med 4(11):1–7
20. Chillemi C, Mantovani M, Osimani M, Castagna A (2017) Arthroscopic transosseous rotator cuff repair: the eight-shape technique. Eur J Orthop Surg Traumatol 27(3):399–404
21. Petri M, Greenspoon JA, Millett PJ (2015) Arthroscopic superior capsule reconstruction for irreparable rotator cuff tears. Arthrosc Tech 4(6):e751-5
22. Hirahara AM, Adams CR (2015) Arthroscopic superior capsular reconstruction for treatment of massive irreparable rotator cuff tears. Arthrosc Tech 4(6):e637-41
23. Adams CR, DeMartino AM, Rego G, Denard PJ, Burkhart SS (2016) The rotator cuff and the superior capsule: why we need both. Arthroscopy 32(12):2628–2637
24. Hartzler RU, Burkhart SS (2017) Superior capsular reconstruction. Orthopedics 40(5):271–280
25. Mihata T, Bui CNH, Akeda M, Cavagnaro MA, Kuenzler M, Peterson AB, McGarry MH, Itami Y, Limpisvasti O, Neo M, Lee TQ (2017) A biomechanical cadaveric study comparing superior capsule reconstruction using fascia lata allograft with human dermal allograft for irreparable rotator cuff tear. J Shoulder Elbow Surg 26(12):2158–2166
26. Sutter EG, Godin JA, Garrigues GE (2017) All-arthroscopic superior shoulder capsule reconstruction with partial rotator cuff repair. Orthopedics 40(4):735–738
27. Hirahara AM, Andersen WJ, Panero AJ (2017) Superior capsular reconstruction: clinical outcomes after minimum 2-year follow-up. Am J Orthop 46:6
28. Mihata T, Lee TQ, Watanabe C, Fukunishi K, Ohue M, Tsujimura T, Kinoshita M (2013) Clinical results of arthroscopic superior capsule reconstruction for irreparable rotator cuff tears. Arthroscopy 29(3):459–470
29. Dierickx C, Ceccarelli E, Conti M, Vanlommel J, Castagna A (2009) Variations of the intra-articular portion of the long head of the biceps tendon: a classification of embryologically explained variations. J Shoulder Elbow Surg 18(4):556–565

30. Chen CH, Chen CH, Chang CH, Su CI, Wang KC, Wang IC, Liu HT, Yu CM, Hsu KY (2012) Classification and analysis of pathology of the long head of the biceps tendon in complete rotator cuff tears. Chang Gung Med J 35(3):263–270
31. Chillemi C, Petrozza V, Franceschini V, Garro L, Pacchiarotti A, Porta N, Cirenza M, Salate Santone F, Castagna A (2016) The role of tendon and subacromial bursa in rotator cuff tear pain: a clinical and histopathological study. Knee Surg Sports Traumatol Arthrosc 24(12):3779–3786